**Goal:**

At the end of this lecture the students should be acquired complete knowledge about fetopelvic relationships

**Specific objectives:**

**At the end of this lecture every student should be:**

1. Identify the bones of the vault of the fetal skull
2. Explain suture of fetal skull
3. Describe the regions and diameters of fetal skull in the mechanism of moulding.
4. Explain the mechanism of moulding.
5. Define the terms related to fetopelvic relationship
6. Identify position and presentation of the fetus

**Introduction:**

The fetal head is large in comparison with the true pelvis, therefore some adaptation between skull and pelvis must take place during labor, the knowledge of the landmarks and measurements of the skull enables midwife to recognize normal presentations and position and to facilitate delivery with the least possible trauma to mother and the baby.

**Terms related to feto pelvic relationship:**

Molding: it is the case where the fetal skull bones are overlapped to decrease head diameter to pass through the birth canal.

- Occurs with descent of the fetal head into the pelvis to reduce the head circumference

**Degree of moulding:**

Assessed vaginally

0 suture lines are separate

+1 suture lines meet

+2 suture lines overlap but can be reduced by gentle digital pressure

+3 overlap irreducible

Station: it is the relationship between fetal presenting part (mostly head) to the ischial spines (-3/-2/-1/0/+1/+2/+3).

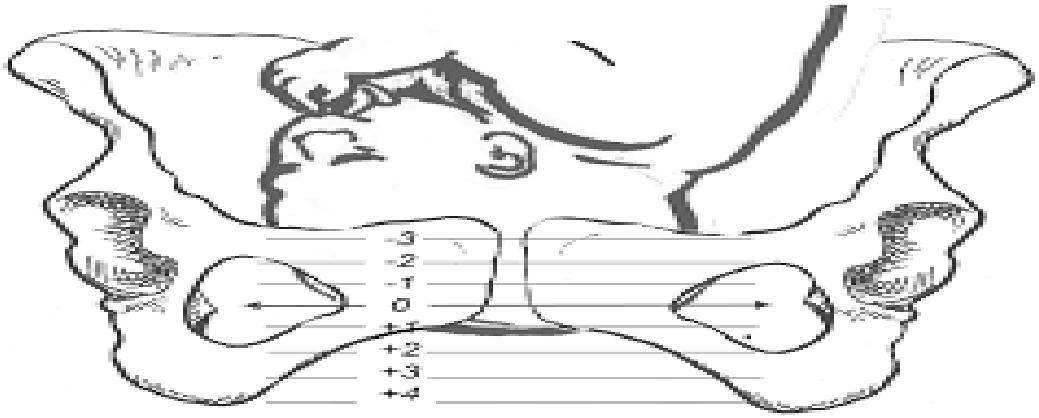


Fetal Lie: it is the Relation between long axis of the fetus to long axis of the mother (longitudinal / oblique / transverse).

Fetal Attitude: it is the relationship between fetal parts to each other (flection / extension).

Fetal Presentation**:** The part of the fetal body that enters (or presents to) the maternal pelvis. Most common = cephalic presentation (head first).

**Fetal presentation** means the part of the fetus that is "presenting" at the cervix:

- **Cephalic presentation** means head first. This is the normal presentation.
- **Breech presentation** means the fetal buttocks is coming out first.

- **Shoulder presentation** means that the fetal shoulder is trying to come out first.

## Fetal Position

- ☞ Refers to the relationship of an assigned area of the presenting part (often called the fetal denominator) to the maternal pelvis. Determine the fetal denominator.
- ☞ Mentally divide the maternal pelvis into 4 quadrants (R&L anterior, R&L posterior).
- ☞ Assign a standard abbreviation indicating the fetal position based on findings of vaginal exam.

### Occiput Anterior (OA)

- ☞ Occiput anterior is usually the easiest position for the fetal head to traverse the maternal pelvis.
- ☞ Shown here is the "direct OA" position. While some fetuses deliver in this position, others deliver slightly rotated clockwise (LOA) or counterclockwise (ROA).
- ☞ The fetus is still considered to be an "anterior" position.

### Left Occiput Anterior (LOA)

The fetal position is often described using three letters.

This is an example of LOA, meaning:

- ☞ Left
- ☞ Occiput
- ☞ Anterior

In other words, the fetal occiput is directed towards the mother's left, anterior side.

**Right Occiput Anterior (ROA)**

- ☞ This is an example of ROA, meaning:
- ☞ Right
- ☞ Occiput
- ☞ Anterior
- ☞ These anterior presentations (ROA and LOA) are normal and usually are the easiest way for the fetus to traverse the birth canal.

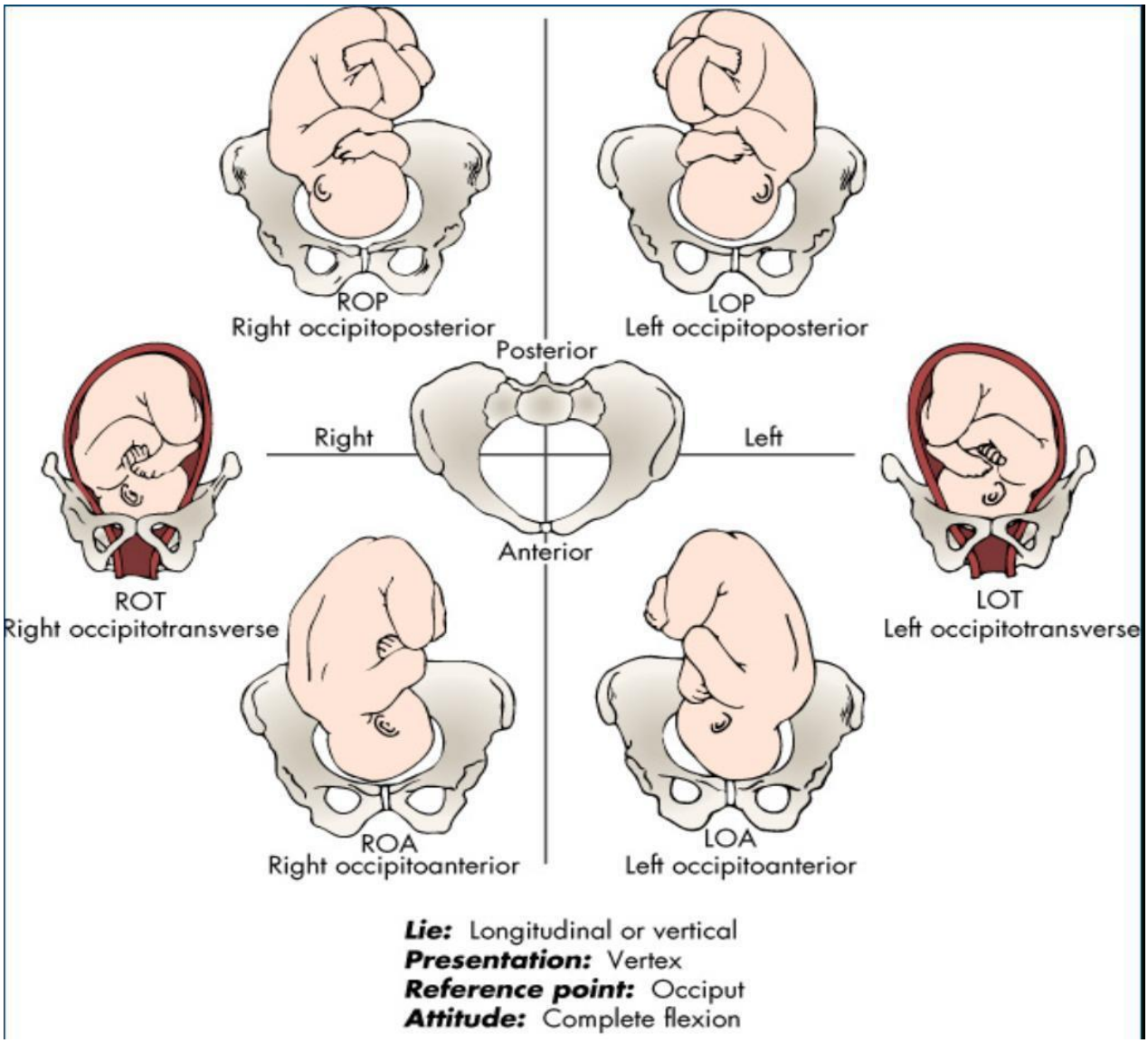

## Fetal Skull:

- **Is consists of** Bones, Sutures, and Fontanels& Landmarks.
- The skull is consists of three parts: **face , the vault & the base**
- The bones of the face & base are heavy & fused
- **The bones of the vault are** 2 frontal, 2 parietal & occipital **fontanels:**

**Fontanelles**: The fontanelles are areas of the head where suture lines intersect.

- **Anterior fontanels or bregma**: diamond shaped is formed by meeting of frontal, sagittal and two coronal sutures and normally closes by time the child is 18 month old
- **Post font** (lambda): Triangle shaped and is formed by meeting of the sagittal and two lambdoidal sutures and normally closes by 6 week of age.

## Fetal Skull Sutures:

**Sutures:** are membranous spaces between the bones of the fetal head.

- **Frontal suture:** It is between 2 frontal bones.

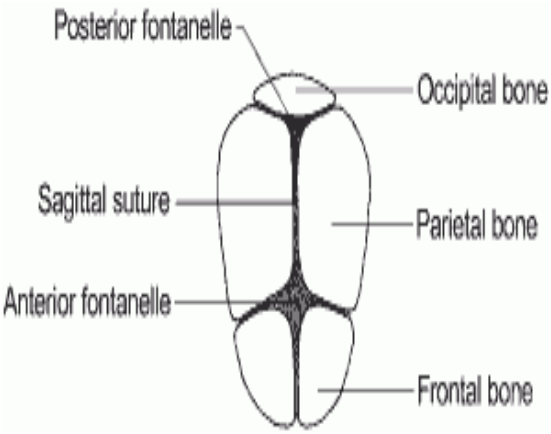

- **Sagittal suture**: It is between 2 parietal bones.
- **Coronal suture**: there are two coronal sutures, each between parietal & frontal bones on either side of head.
- **Lambdoidal suture**: There are two lambdiodal sutures, each between the parietal bones &the upper margin of occipital bone on either side of head.
- **Temporal suture: between inferior margin of the parietal & temporal**

**Landmarks of the fetal skull**

**Position and presentation assessed by:**
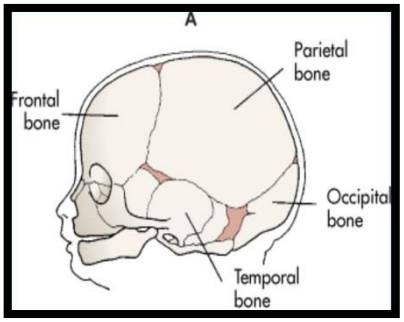
- Pelvic Exam
- Abdominal Exam (Leopold's Maneuvers)
- Ultrasound if available.